



NORTH
Dakota
Be Legendary.™

Health Information Network
INFORMATION TECHNOLOGY




Viewing Radiology Images

51



Viewing Radiology Images

- Login/access NDHIN per usual method
- Access patient record per usual method
 - Patient search or
 - Direct access to patient record per EHR-NDHIN link
 - See previous training if necessary



NORTH
Dakota
Be Legendary.™

Health Information Network
INFORMATION TECHNOLOGY

52

Radiology Reports

- Radiology folders are organized by radiology test type
- Information is displayed as received from sending facility
- Unread reports are displayed in bold
- Findings section includes Report History and Access History

Clinical Documents 🔍 🔄 👁

Showing All [Mark All As Read](#)

Group By [Category](#) Sort By [Date](#)

- ▶ Patient Summary
- ▶ PDMP
- ▶ NDIIS Immunizations
- ▶ Vital Signs Flow Sheet
- ▼ Dynamic Documents (1)
 - ▶ Patient Snapshot
- ▶ Laboratory (68)
- ▶ Microbiology (7)
- ▶ Radiology (10)
 - ▼ CAT Scan (4)
 - Apr-19-2006 Chest CT [TRIN] Dr Timothy Orange**
 - May-04-2005 Chest CT [TRIN] Dr Timothy Orange
 - Mar-22-2005 Cranial CT Scan [TRIN] Dr Alerberto Jos
 - Jan-09-2005 Abdominal-Thoracic CT Scan [TRIN] Dr
 - ▶ Radiology (6)
- ▶ Transcribed Documents (9)

Chest CT [TRIN] (14 years ago)

Chest CT

Performed	Apr-19-2006 22:00	Order Number	CHESTCT1h13
Ordering Provider	Dr Timothy Orange	Status	Final

Findings Final

CT sections show a poorly defined thick walled lesion involving the anterior and superior lingular segments of the left upper lobe. The surrounding lung parenchyma shows areas of consolidation. Mediastinal structures normal. Possible lymph node enlargement seen. Soft tissue and fluid attenuation values noted within the lesion. A few specks of calcific density also imaged in the wall of the lesion, and show enhancement following contrast administration. No pleural effusion/ pleural thickening noted.

Report History

53

Radiology Reports

- Reports are housed in the Clinical Documents
- Use search shortcut/navigation tools to find reports

Clinical Documents 🔍 🔄 👁

Showing All [Mark All As Read](#)

Group By [Category](#) Sort By [Date](#)

- ▶ Patient Summary
- ▶ PDMP
- ▶ NDIIS Immunizations
- ▶ Vital Signs Flow Sheet
- ▶ Dynamic Documents (1)
- ▶ Laboratory (68)
- ▶ Microbiology (7)
- ▶ Radiology (10)
- ▶ Transcribed Documents (9)

Show: [All](#)

Group By: [Category](#)

Sort By: [Date](#)

[Apply](#) [Cancel](#)

- View Patient Summary
- Access PDMP
- Access NDIIS Immunizations
- View Vital Signs Flow Sheet
- Generate a CCD
- View lab results
- View radiology reports
- View a range of clinical documents

Navigation tools

Show: All | Last 72 hours | Last 14 days | Last 3 months | Last ... | Specific Range

Group By: Category | Date | Service | Author

Sort By: Date | Service | Author

54

Radiology Images

- Select the Image to view by checking the box in front of the desired study then clicking 'View Studies'
- May check multiple boxes for comparisons
- Status:
 - Green – readily available for 30 days
 - Yellow – archived but can select the option to retrieve. Once retrieved status changes to green and study remains readily available for 30 days.

MOUSE, Mickey SEX Male DOB Feb-10-1947 (73y)

Patient Summary
 Medicines Viewer
 Timeline
 External Record
 Images
 Circle of Care
 Laboratory Results Flow Sheet

John Q Cardinal DOB: 11/09/1949 Gender: M

Available Studies for This Patient

	Status	MRN	Location	Study Date	Study Description
<input type="checkbox"/>		84568-4564	TRINITY	12/29/2017	Emergent CT
<input type="checkbox"/>		84568-4564	TRINITY	11/13/2014	CT CERVICAL SPINE WITHOUT IV CONTRAST
<input type="checkbox"/>		84568-4564	TRINITY	07/18/2010	CT CERVICAL SPINE WITHOUT IV CONTRAST
<input type="checkbox"/>		84568-4564	TRINITY	07/18/2010	CT CERVICAL SPINE WITHOUT IV CONTRAST

Check the box to indicate which study to view

55

Radiology Images

This is an example of what the Image Page can look like with an archived image status indicator. Click the yellow button to load the image, then click the square box to view it.

John Q Cardinal DOB: 11/09/1949 Gender: M

Available Studies for This Patient

	Status	MRN	Location
<input type="checkbox"/>		84568-4564	TRINITY
<input type="checkbox"/>		84568-4564	TRINITY
<input type="checkbox"/>		84568-4564	TRINITY
<input type="checkbox"/>		84568-4564	TRINITY

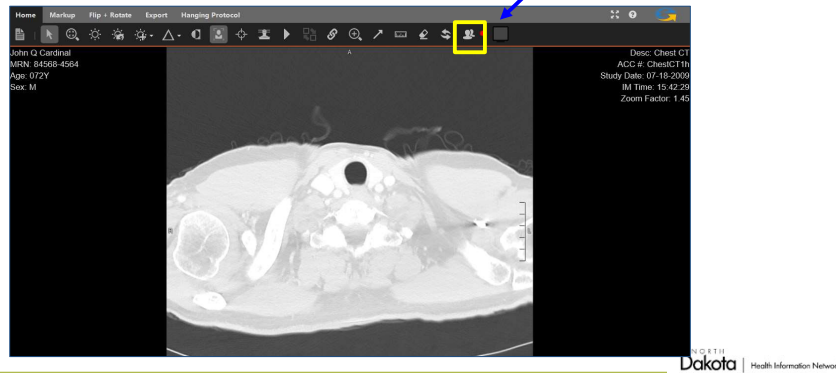56

View and Share Images

Another Authorized User may share the session by logging into the NDHIN Clinical Portal, accessing the same patient and Image and clicking the option to share session.

- Use Cases
 - Consultation
 - Emergency room transfer

Share image icon



57

Who You Going to Call? NDHIN Outreach Coordinators!

Sarah J. Miller
NDHIN Outreach Manager
(701) 324-7430
sarmiller@nd.gov

Tracey Regimbal, RHIT
NDHIN Outreach Coordinator
(701) 739-2732
tracey.regimbal@healthtechsolutions.com

Natasha Green, MBA, RN
NDHIN Outreach Coordinator
(701) 989-6226
natasha.green@healthtechsolutions.com

Patti Kritzberger, RHIT, CHPS
NDHIN Outreach Coordinator
(701) 989-6235
patti.kritzberger@healthtechsolutions.com

Lisa Thorp, BSN, RN, CDE
NDHIN Outreach Coordinator
(701) 989-6241
lisa.thorp@healthtechsolutions.com



Help Desk @ (844)335-6253
email NDHINsupport@koblegroup.com

58